



The post-op chest

Trachea and bronchi

What will I gain from this video?

After watching this video, you will know how to recognize radiological features related to tracheal and bronchial surgery.

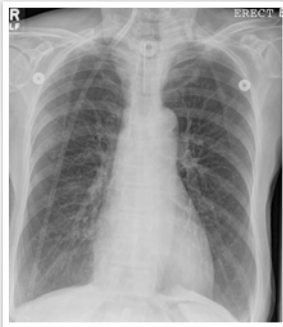Complications related to surgery—EARLY

- Pneumothorax
- Pneumomediastinum
- Subcutaneous emphysema
- Bleeding and aspiration of blood

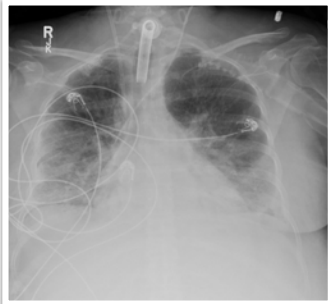
Complications related to surgery—LATE

- Tracheo-esophageal fistula
- Tracheal stricture

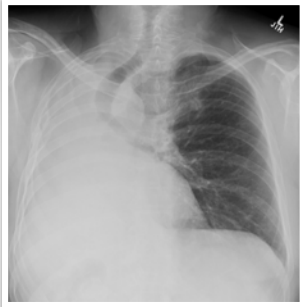
Tracheostomy



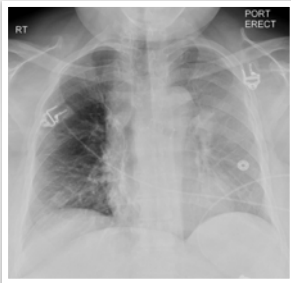
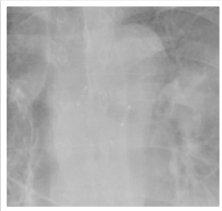
Tracheostomy



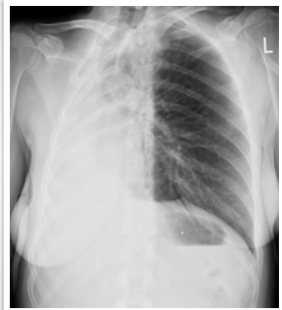
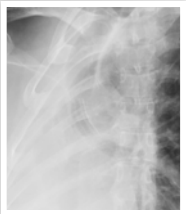Pneumonectomy



**Tracheal/bronchial
stent**



**Tracheal/bronchial
stent**



Always compare to previous X-rays to identify complications.

Understand what type of surgery was performed.
Appearance will depend on type of surgery.

Early and late postoperative complications can occur.
